



DOI: 10.4274/qrheumatol.galenos.2023.22931

Rheumatology Quarterly

RICH SKIN MANIFESTATIONS IN DERMATOMYOSITIS

© Serkan Günaydın, © Ahmet Karataş

Firat University Faculty of Medicine, Department of Rheumatology, Elazığ, Turkey

Keywords: Dermatomyositis, skin, muscle weakness

INTRODUCTION

A 49-year-old female patient presented with complaints of pain and weakness in the shoulders, arms, and legs. About 2 weeks after the complaint of pain and weakness, purplish-red discolorations started on her face, around her eyes, and later on her neck and upper chest. She presented to us with purplish discoloration around her eyes (Figure 1A) and diffuse red-purple discoloration on the neck and upper chest. Additionally, raised lesions of pink-purple skin were observed on the extensor surfaces of the proximal interphalangeal joints on the hands, elbows, and knees (Figure 1B and 1C). Laboratory

examination revealed creatine kinase (CK): 549 U/L, aspartate aminotransferase: 61 U/L, alanine aminotransferase: 58 U/L, CR: 0.49 mg/dL, erythrocyte sedimentation rate: 54 mm/hour, antinuclear antibodies (ANA), and ANA subgroups were negative.

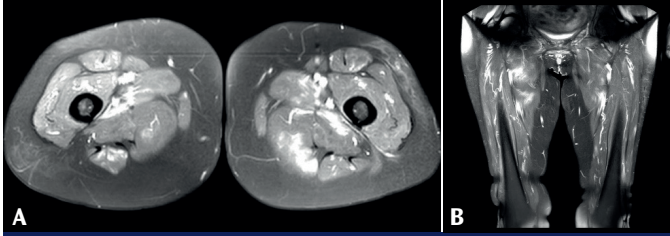
In magnetic resonance imaging, signal increase in T2 images and local contrast enhancement in post-contrast series were observed in bilateral thigh muscles (Figure 2A and 2B). In view of current clinical and laboratory findings, the patient was diagnosed with dermatomyositis and was started on methyl prednisolone 120 mg/day (intravenous), hydroxychloroquine 2x200 mg, methotrexate 15 mg/week (peroral), folic acid 5

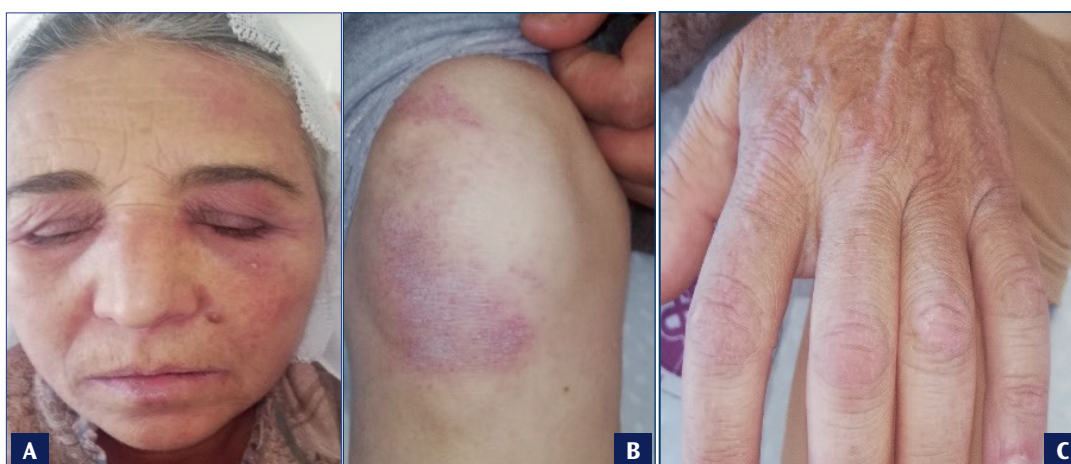

Figure 1. A. Bilateral lilac discoloration of the eyelids, B. Violaceous skin changes over the knees (Gottron sign), C. Gottron papules on the finger joints

Address for Correspondence: Serkan Günaydın, Firat University Faculty of Medicine, Department of Rheumatology, Elazığ, Turkey**Phone:** +90 533 547 48 52 **E-mail:** drserkangunaydin@hotmail.com **ORCID ID:** orcid.org/0000-0002-1131-2531**Received:** 23.11.2022 **Accepted:** 24.01.2023

mg/week, and calcium/vitamin D supplementation. On the 5th day of her treatment, she regressed to CK: 161 U/L and lactate dehydrogenase: 277 U/L. The patient, whose complaints of muscle weakness decreased and skin lesions started to regress, was discharged with a steroid dose reduction schedule, with the recommendation of outpatient control (1).



Figures 2A-B. Bilateral muscular edema of the thigh muscles

Ethics

Informed Consent: Written informed consent was obtained from the patients who participated in this study.

Peer-review: Externally peer-reviewed.

Authorship Contributions

Surgical and Medical Practices: S.G., A.K., Concept: S.G., Design: S.G., A.K., Data Collection or Processing: S.G., A.K., Literature Search: S.G., Writing: S.G.

Conflict of Interest: No conflict of interest was declared by the authors.

Financial Disclosure: The authors declared that this study received no financial support.

REFERENCE

1. Dalakas MC. Inflammatory muscle diseases. *N Engl J Med* 2015;372:1734-47.